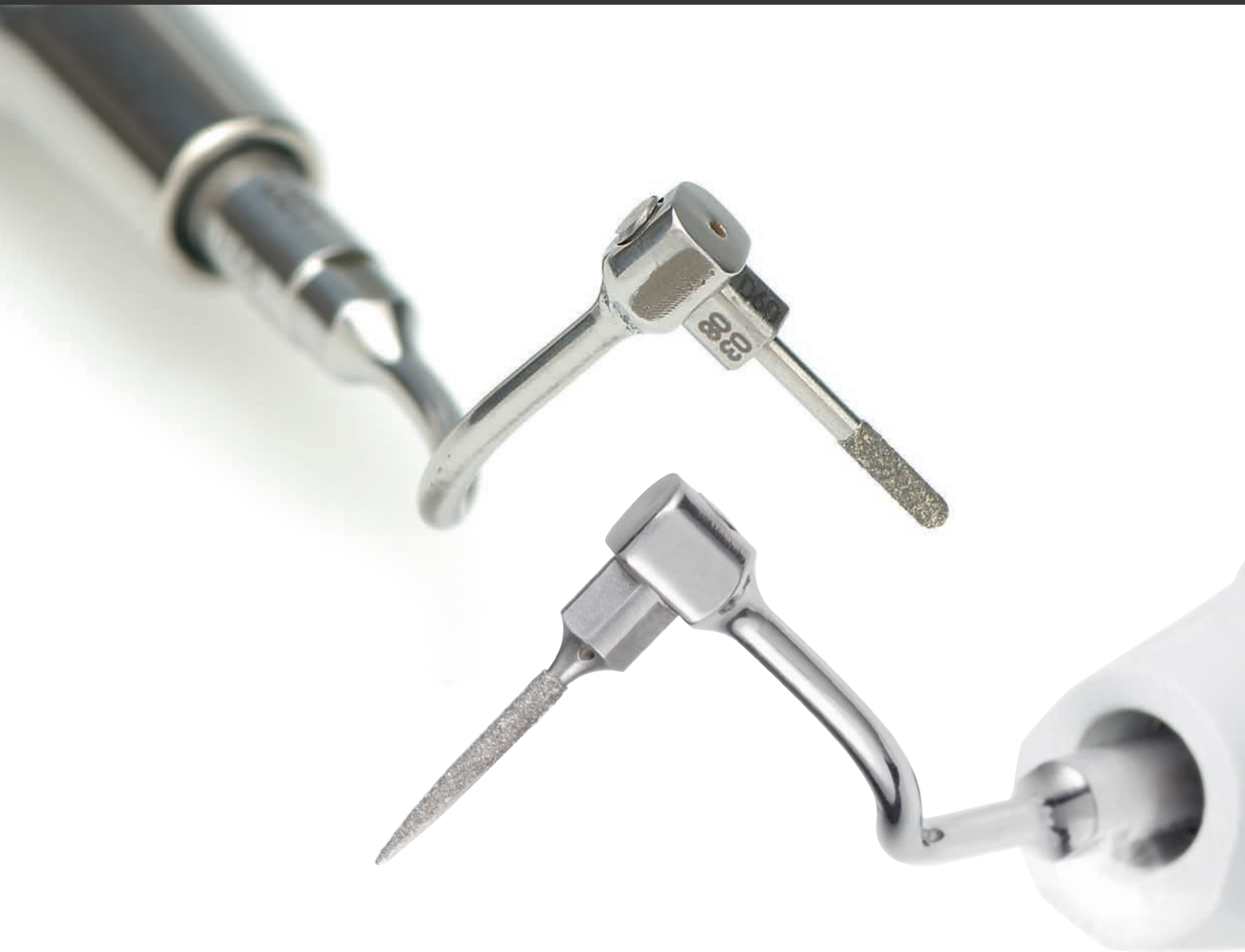

→ MECTRON CROWN PREP TIPS ULTRASONIC CERVICAL FINISHING – ATRAUMATIC AND PRECISE



**crown prep tips – optimal control and ergonomics,
thanks to the unique movement of the tips**

The unique shape of the tip holder provides a superb view of the field during preparation and elliptical-like movement of the crown prep tip. The ultrasound vibrations preserve the soft tissues. The versatility of this technique makes it possible to prepare the margin with both the chamfer and vertical preparation techniques.

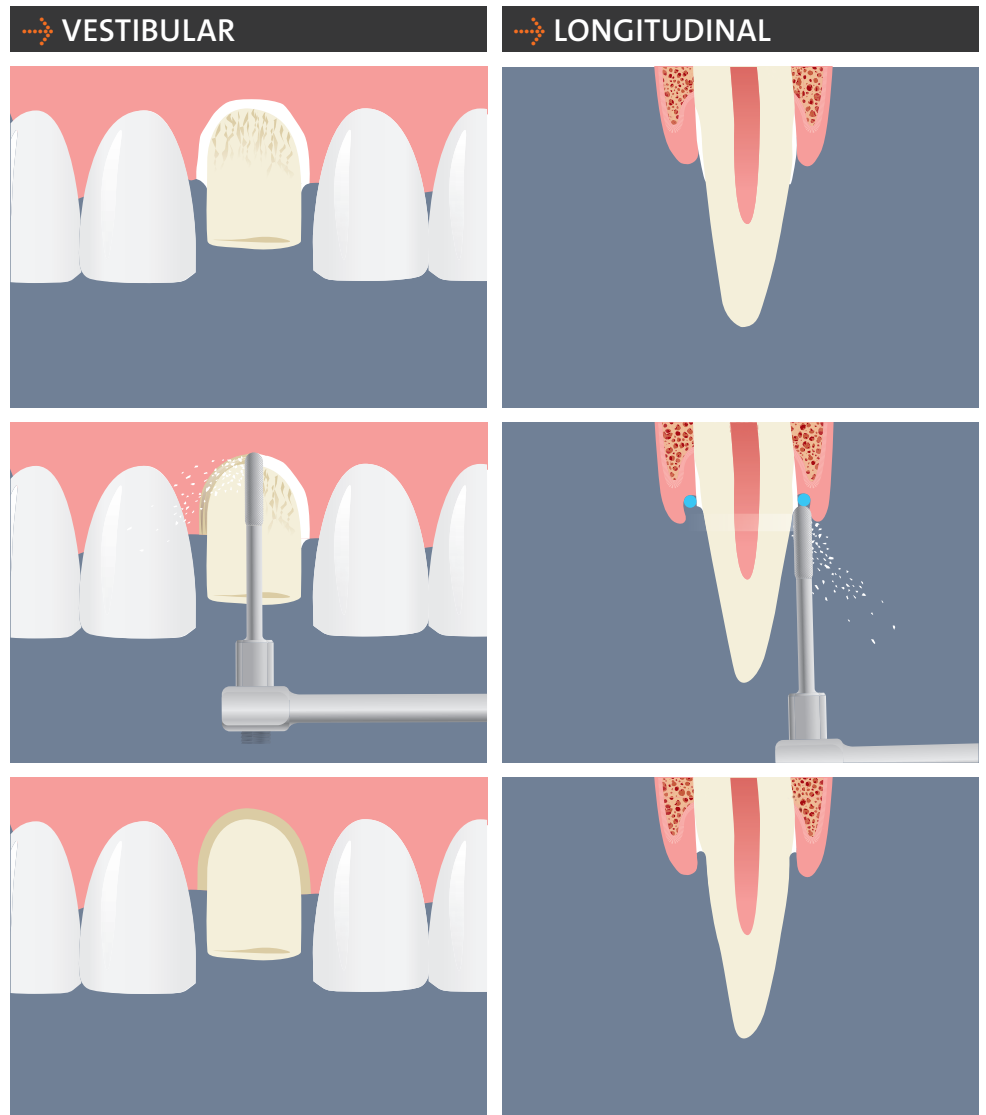
mectron

STEP BY STEP

METHOD OF USE

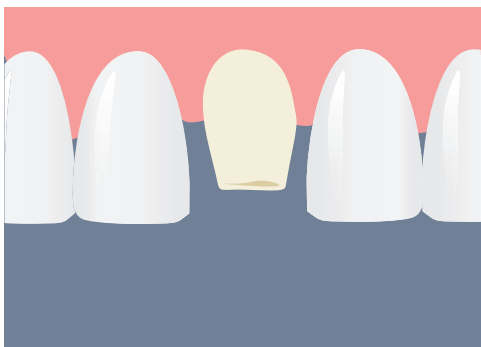
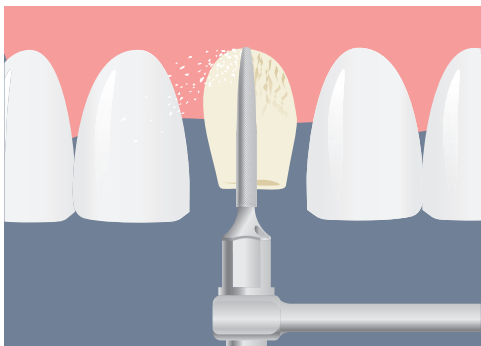
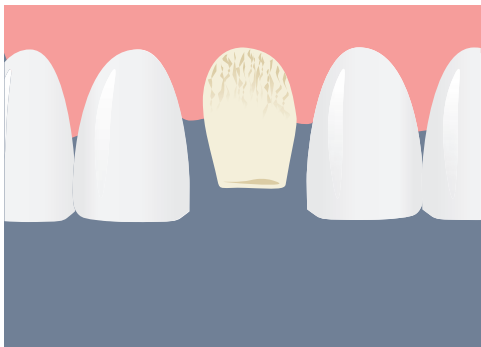
Use of the crown prep tip requires minor back-and-forth movements, always maintaining contact with the tooth. The special shape and unique movement of the tip makes it possible to work all the way around the tooth without changing position.

PREPARATION WITH CHAMFER TECHNIQUE


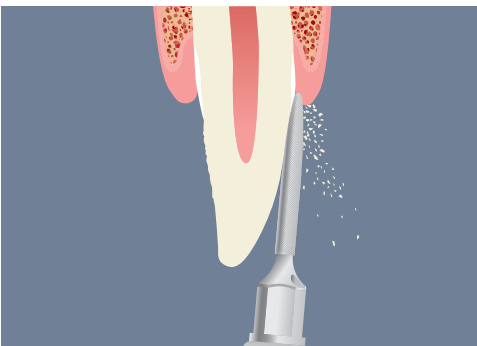
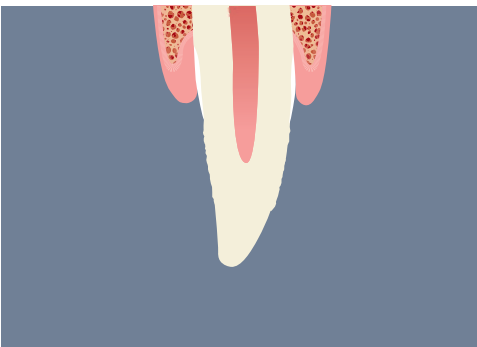


- 1 After initial preparation – performed with coarse bur – the cervical margin is rough and has not yet been positioned at the subgingival level.
- 2 Positioning of the non-impregnated retraction cord of a size suitable for the periodontium.
- 3 The diamond-coated crown prep tip D120 is used first, as it is more aggressive and thus removes the remaining enamel and dental material faster.
- 4 To obtain a more uniform preparation margin, crown prep tip D90 is then used.
- 5 Subsequently, diamond-coated crown prep tip D60 is used to even out the preparation obtained and to start smoothing and polishing the dentinal tissue to obtain a smooth microstructure.
- 6 The obtained cervical margin is extremely precise, which enables the operator to take a better quality impression. This, in turn, guarantees a perfect fit and longer life span for the dental restoration.

→ VESTIBULAR



→ LONGITUDINAL



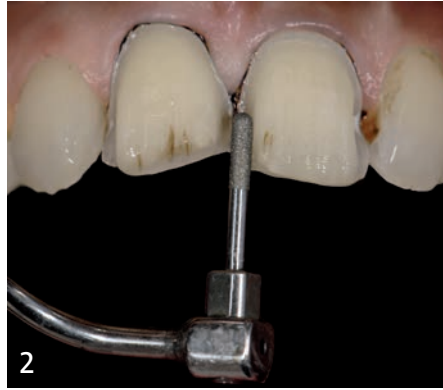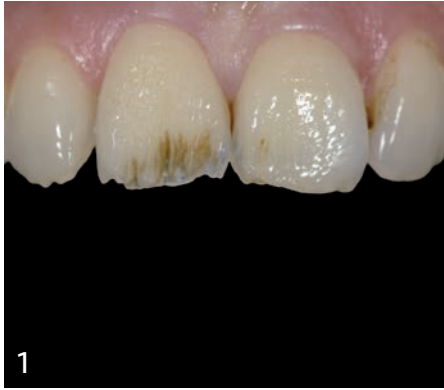→ PREPARATION WITH VERTICAL PREPARATION TECHNIQUE



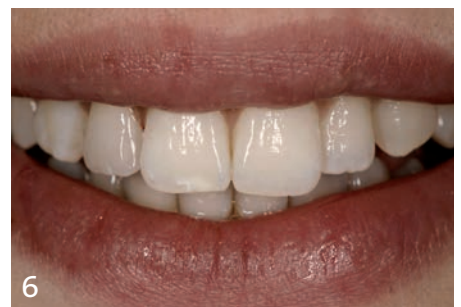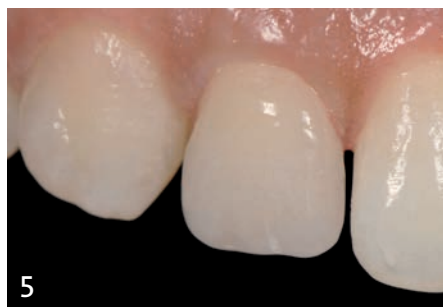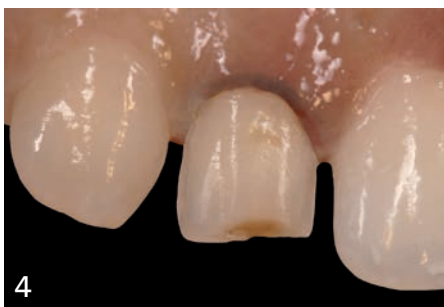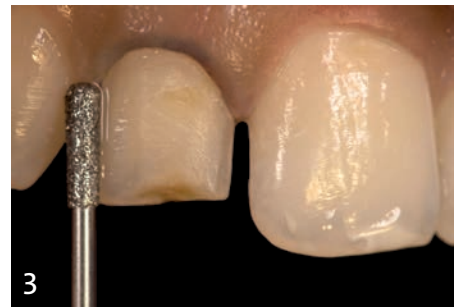
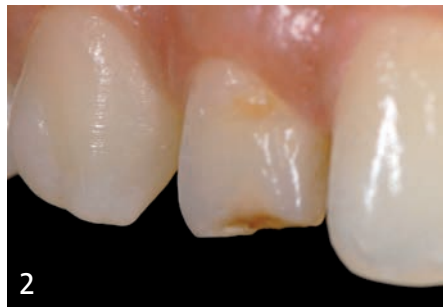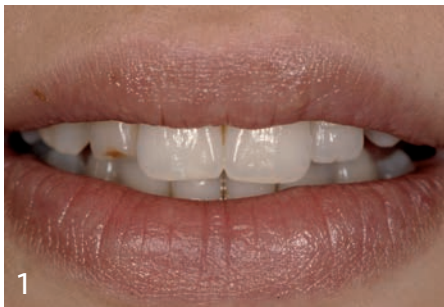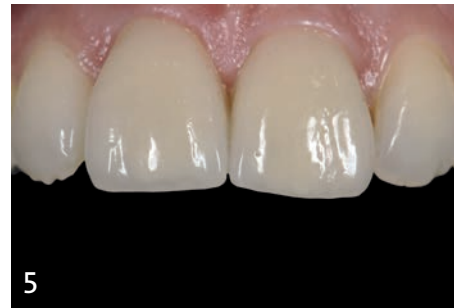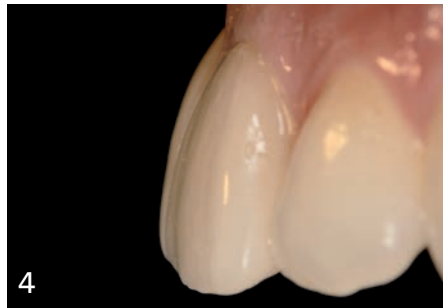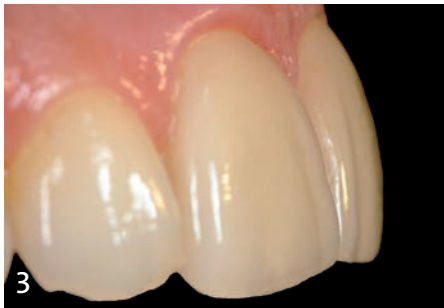- 1 Following preparation of the tooth – performed with coarse-grained burs – the preparation margin is rough and irregular.
- 2 A bur of the same size as the previous one, but with finer grain, is used smooth out the surface of the tooth. Since there is bleeding due to the “Gingival curettage” – caused by the burs working at the subgingival level – the conditions offer poor visibility, and thus the final dental surface is irregular and imprecise.
- 3 These defects need to be corrected in the final impression-taking session. A vertical crown prep tip D90 is used to obtain a more uniform dental surface.
- 4 Subsequently, a diamond-coated crown prep tip D60 is used to finalize the preparation obtained, smoothing and polishing the dentinal tissue.
- 5 After using the diamond-coated crown prep tip D60, the surface microstructure will be smooth. The cervical margin thus obtained is extremely precise, which enables the operator to take a better quality impression. This, in turn, guarantees a perfect fit and longer life span for the dental restoration.

CLINICAL CASES

PREPARATION WITH THE CHAMFER TECHNIQUE



- 1 Initial situation
- 2 Finishing of the margin with crown prep tip D60
- 3 Gingival veneer integration (right)
- 4 Gingival veneer integration (left)
- 5 End result

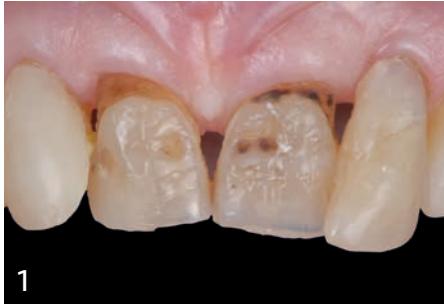

- 1 Initial smile
- 4 Finished dental surface

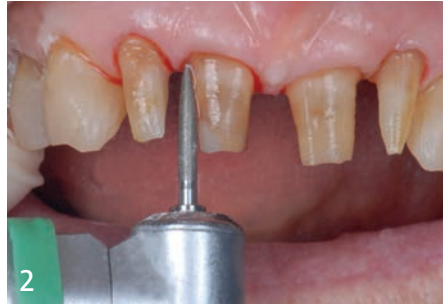- 2 Tooth to be treated D120
- 5 Veneer in situ

- 3 Preparation with crown prep tip
- 6 Final smile

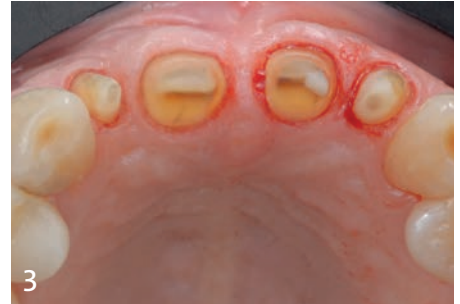➔ PREPARATION WITH THE VERTICAL PREPARATION TECHNIQUE



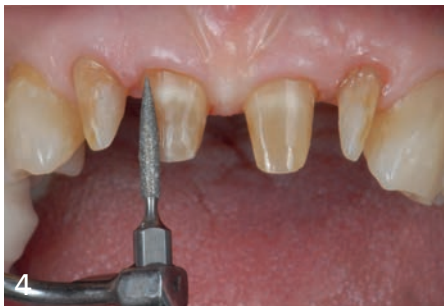1



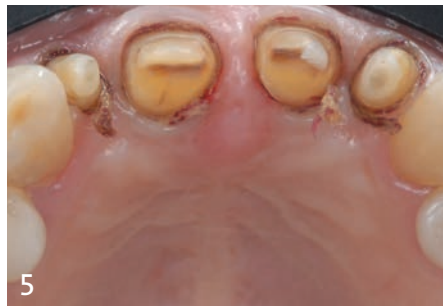2



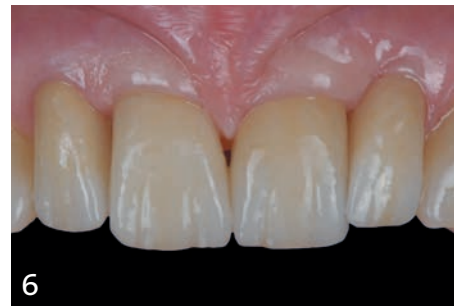3



4



5



6

1 Initial situation

2 Vertical preparation with bur

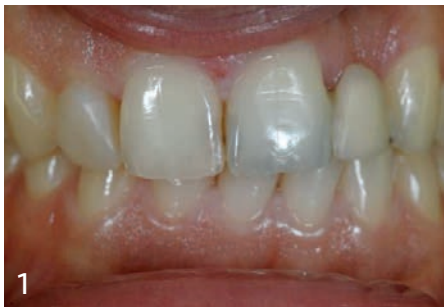3 Condition of gingival tissue after using the bur

4 Ultrasonic finishing of vertical preparation with dedicated tip

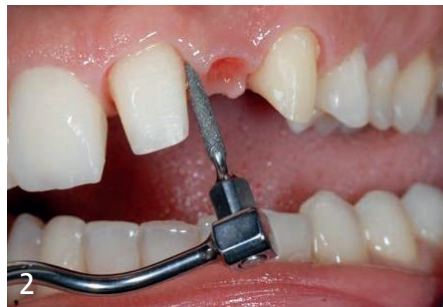5 Condition of gingival tissue after finishing and positioning of retractor cord for subsequent impression

6 Gingival veneer integration and end result

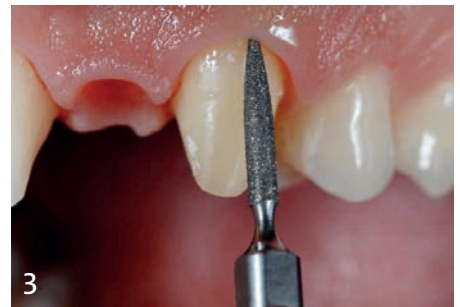Clinical case courtesy of Dr. Domenico Baldi (Genoa, Italy)



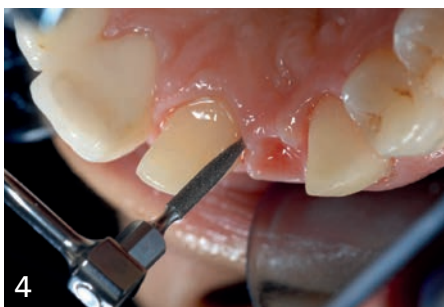1



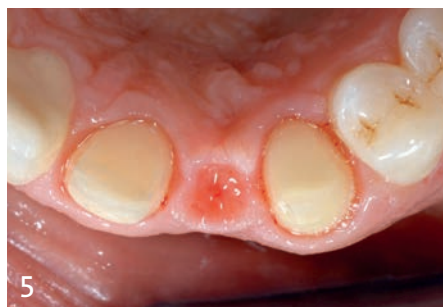2



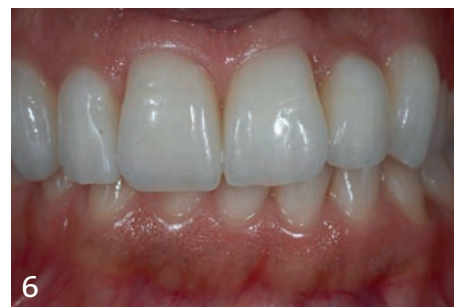3



4



5



6

1 Initial situation

2 Finishing of central intrasulcular area

3 Finishing of canine intrasulcular area

4 Finishing of palatal area

5 Condition after finishing the two stumps

6 End result

Clinical case courtesy of Dr. Fiammetta Sinigaglia (Varese, Italy)

→ CROWN PREP TIPS

→ CHAMFER TECHNIQUE

Mectron offers 8 different crown prep tips for the tip holder. For finishing the closure margin, it is advisable to use a crown prep tip of the same diameter as the bur used for initial preparation.

→ LENGTH 10 MM	→ DIAMOND COATING		
diameter	D120	D90	D60
1.2 mm		TA12D90	TA12D60
1.4 mm	TA14D120	TA14D90	TA14D60
1.6 mm	TA16D120	TA16D90	TA16D60



→ ADVANTAGES

1. Greater precision
2. Less bleeding
3. Mini-invasive
4. Fewer prosthetic treatment sessions
5. Reduced time to delivery of prosthesis

→ VERTICAL PREPARATION TECHNIQUE



Mectron offers 4 different crown prep tips for the tip holder. For finishing of the closure area, it is advisable to use a crown prep tip of the same diameter as the bur used for initial preparation.

→ LENGTH 10 MM	→ DIAMOND COATING	
diameter	D90	D60
1.2 mm	TF12D90	TF12D60
1.6 mm	TF16D90	TF16D60

THE SYSTEM FOR PIEZOSURGERY® AND ULTRASOUNDS

a perfect combination for maximum ergonomics – available for all mectron ultrasonic and PIEZOSURGERY® devices

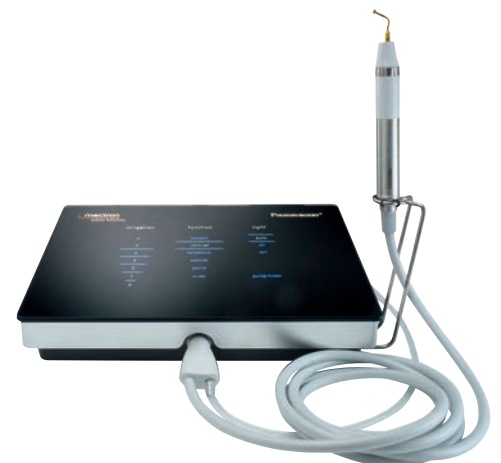
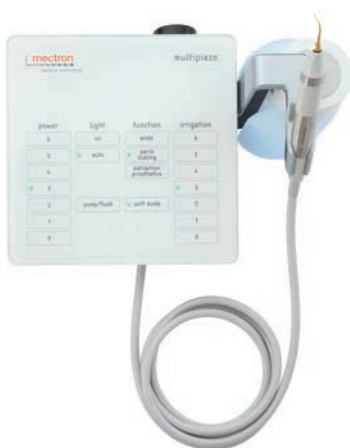
→ ADAPTOR AB1
Used for secure the crown prep tip in the tip holder



→ TORQUE WRENCH K7
Special wrench to tighten the tip holder on the mectron ultrasound handpiece

→ TIP HOLDER DB
Support to hold the crown prep tips, specially bent to provide a superb view during preparation and elliptical-like movement of the crown prep tip



mectron s.p.a.,
via Loreto 15/A, 16042 Carasco (Ge), Italy,
tel +39 0185 35361, fax +39 0185 351374

 www.mectron.com – mectron@mectron.com

© Copyright Mectron S.p.A., Carasco, Italy
All rights reserved. Text, images and graphics contained in Mectron brochures are protected by
copyright and other property rights laws. The content cannot be copied, disclosed, modified or made
accessible to third parties for commercial purposes without written permission from Mectron S.p.A.